

Laxative effect of bitter almond (*Amygdalus communis* var. *amara*)

Hamid Reza Kazerani^{1*}, Seddigeh Jalali²

¹Department of Physiology, Faculty Veterinary Medicine, Ferdowsi University of Mashhad, Mashhad, Iran

²Department of Biology, Payame Noor University, Tehran, Iran

Received: February 8, 2013

Accepted: March 10, 2014

Abstract

The possible laxative and prokinetic effects of bitter almond were studied: 1- two groups of 7 rats were gavaged with ethanol extract of bitter almond (500mg/kg) or placebo and the number of feces, fecal weight and its percentage of water were studied 18-24h thereafter. 2- Ethanol extract of bitter almond (125 or 250mg/ml), lactulose (as positive control) or placebo was randomly injected into jejuna segments in anesthetized rats (n=9). The volume of the fluid in each segment was measured after 1h. 3- Gastrointestinal (GI) transit time was studied in rats treated with the extract or placebo using phenol red. The rats were sacrificed at times 30min, 1, 2 and 4h. ethanol extract of bitter almond at 500mg/kg significantly increased fecal weight and water. It had no significant effects on the osmotic infiltration of fluid into the intestine or on the transit time of the contents in the GI tract. The current results suggest that bitter almond has a laxative effect that seems to be due to malabsorption of electrolytes and water via enterocytes.

Keywords: bitter almond, *Amygdalus communis* var. *amara*, laxative, prokinetic

*Corresponding author: Hamid Reza Kazerani
Email: kazerani@um.ac.ir

Introduction

Bitter almond is the seed of the small green almond fruit of the bitter almond tree (*Amygdalus communis* var. *amara*). It is very similar to sweet almond but has a bitter taste. It contains different bioactive ingredients including amygdalin, which is the main determinant of the bitter taste (Sánchez-Pérez *et al.*, 2008). This compound is also found in the stones of apricot, cherry, plum and peach. Amygdalin, as well as its synthetic form, laetrile, have been subject to extensive research due to their allegedly anti-cancer effects (Greenberg, 1980, Vickers, 2004, Milazzo *et al.*, 2007). Anti-inflammatory, analgesic and antinociceptive effects have been also suggested for this ingredient (Hwang *et al.*, 2008, Lin and Lin, 2011). Moreover, amygdalin has shown protective effects against alloxan induced diabetes in mice (Heikkila and Cabbat, 1980). Finally, recent studies suggest beneficial effects for this compound against atherosclerosis (Jiagang *et al.*, 2011). This glucoside, however, is cyanogenic, yielding the fatal toxin, hydrogen cyanide, in the presence of the enzyme emulsin, contained in bitter almond (Newmark *et al.*, 1981, Rietjens *et al.*, 2005).

Bitter almond has different applications in traditional medicine. It has been used to treat neurologic coughs, pertussis, pleurisy, influenza, asthma and taeniasis. Bitter almond has been also used topically in order to soothe neurologic pains, hepatic and kidney colics, migraine and rheumatoid arthritis (Zargari, 1992). It has been also proposed as laxative in ancient books (Mir-Heidar, 1995). The current research was aimed to scientifically examine the laxative effects of the plant in rat.

Methods

Wistar rats of either sex (190-250g) were purchased from Razi Vaccine and Serum Research Institute and were acclimated at experimental conditions for at least 1 week before the start of the experiment.

Good quality bitter almond was obtained

from South Khorasan Razavi Province, Birjand. The dried powder of the seeds were used for preparation of water alcoholic (water/ethanol: 20/80: vol/vol) extract, using a shaker incubator (40°C, 24h). The extract was then passed through a paper filter and was evaporated under flow of N₂ gas for 2-3h. The placebo was prepared following the same procedure with no bitter almond.

The laxative effect of the extract was studied using two experimental groups (n=7 each). The test group was gavaged with a single dose of the extract at 500mg/kg Bw, while the control rats received placebo. The number of excreted feces, fecal weight and its water content were studied 18-24 following administration of the extract or the placebo. To achieve the latter, the samples were weighed both immediately and after drying at 70°C for 20h (Abbaszadeh *et al.*, 2010). It is noteworthy that the dose of the extract (500mg/kg Bw) was chosen according to the preliminary studies suggesting both 250 and 500mg/kg Bw doses were effective, and no apparent toxic effects were observed using the higher dose.

Osmotic infiltration of fluids into the lumen or intestinal secretions due to the treatment was verified in 9 anaesthetized rats (pentobarbital sodium, 60 mg/kg). The abdominal cavity was opened and the jejunum was divided into four segments of 4 cm. A solution (0.3 ml) containing either of the placebo (negative control), lactulose (0.3 g/ml) as the positive control or the extract at two different doses of 125 and 250 mg/ml were randomly injected into each ligated jejunal segments. The fluid volume in each segment was measured after 1 h.

The possible effect of the extract on GI transit time was studied using phenol red as a marker as previously described (Martinez *et al.*, 1998, Arezoomandan *et al.*, 2011). Briefly, 32 rats in groups of 3 were kept in individual cages and were deprived from food but had free access to drinking water. The rats received either the placebo or the extract (250mg/kg Bwt) via a gavage tube, twice with an 18h

interval. Thirty minutes following the second medication, all rats were gavaged with a solution (1.5ml) containing phenol red (3 mg/ml) and methyl cellulose (15 mg/ml). The control and the test groups were then sacrificed using a CO₂ chamber at 30min, 1, 2 and 4h after it. In all cases, the abdomen was opened, the small intestine was cut into 3 equal segments (S1-S3). These segments, together with the stomach, cecum and colon were carefully removed and washed with saline solution. Each segment was homogenized in 100 ml NaOH (1.5N) solution. The suspension was settled at room temperature for 1 h, and then 5 ml of the supernatant was added to 0.5 ml trichloroacetic acid (20%) and was centrifuged (3000 rpm, 30 min, 4°C). The supernatant was added to 4 ml NaOH (0.5 N) and the absorbance was measured at 560 nm (Jenway, UK). The transit time was calculated

according to the amount of phenol red in each segment of the alimentary canal. The geometric center of dye transit was calculated for each animal as $(\sum (\% \text{ dye per segment segment number}) / 100)$.

Statistics

Statistical analysis and drawing of the figures were performed using Graph Pad Prism v5.0 (Graph Pad Software, USA). Statistical comparisons were performed using t-test for feces count and feces water percentage, two-way analysis of variance (ANOVA) followed by Bonferroni posttests for cumulative phenol red and geometric center, and one-way ANOVA followed by Dunnett's test for osmotic infiltration of fluids into the jejunum. In all cases, $p < 0.05$ was considered as significant. Unless otherwise stated, all data are represented as mean \pm SEM.

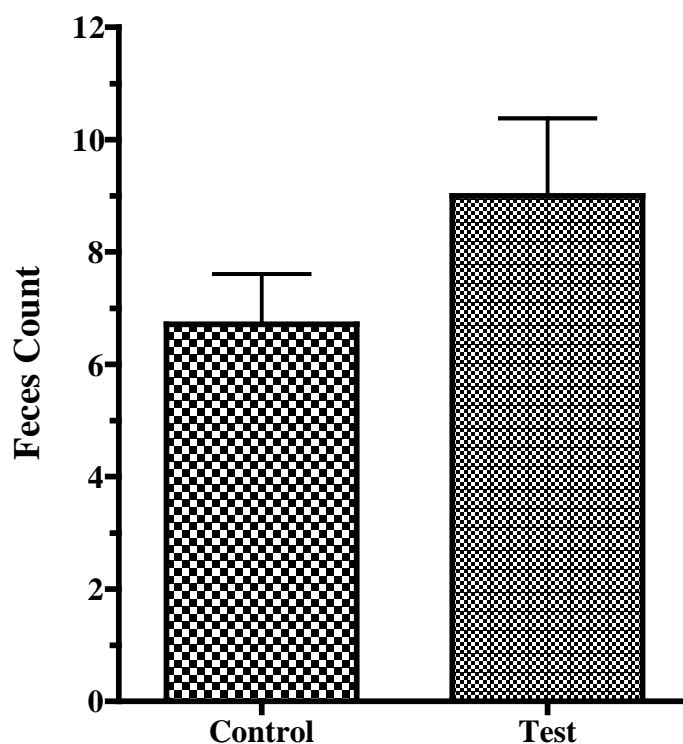


Figure 1. The number of excreted feces 18-24h following intra-gastric administration of alcoholic extract of bitter almond (500mg/kg) or placebo (Control). Data are represented as mean \pm SEM ($P = 0.19$, *t*-test).

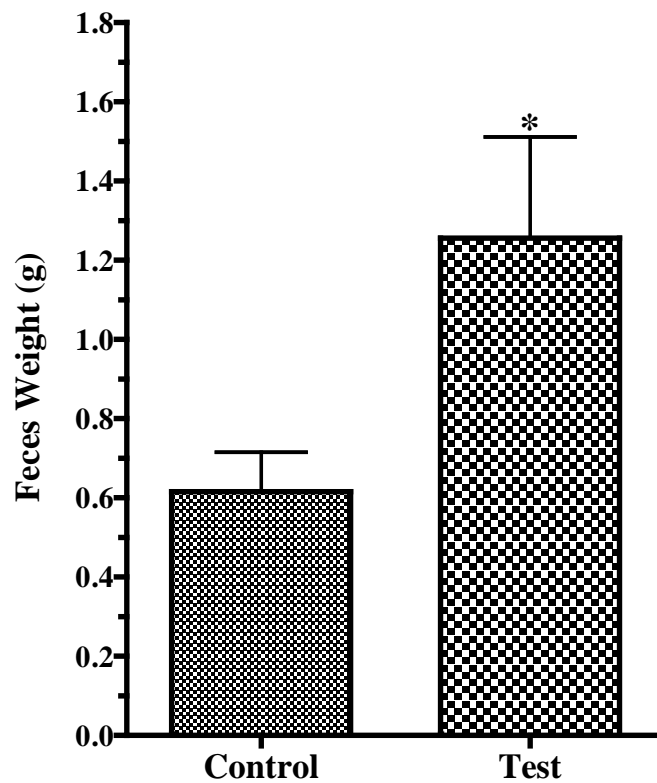


Figure 2. The weights of the fresh feces of rats, 18-24h following gavaged feeding of the alcoholic extract of bitter almond (500mg/kg) or placebo (Control). Data are represented as mean+SEM. The asterisk indicates statistical significance ($p<0.05$, *t-test*).

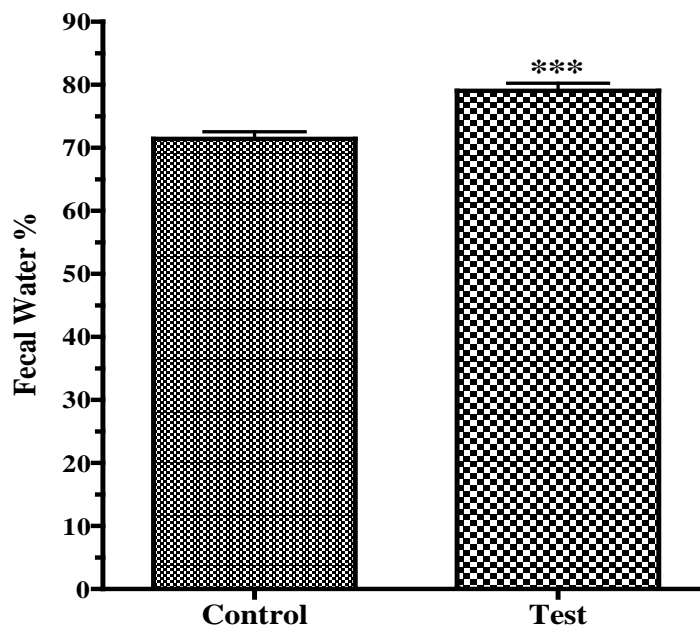


Figure 3. The percentage of fecal water in rats, 18-24h after receiving alcoholic extract of bitter almond (500mg/kg) by gavage compared to the control. Data are represented as mean+SEM. The asterisks indicate statistical significance ($p<0.001$, *t-test*).

Results

The effect of bitter almond extract on numbers of excreted feces was studied during 18-24 h following intragastric administration (Figure 1). The feces number dominated in the test group although the difference is not significant ($p=0.190$). As shown in Figure 2, the weight of the excreted feces in the test group was more than twice that of the control during the second phase ($p<0.05$). Consistently, the percentage of fecal water was significantly higher in the test group during the same period (Figure 3).

The volume of fluids in different segments of the alimentary canal 1 hour following intraluminal injection of placebo, lactulose, or the extract is shown in Figure 4. The fluid volume in jejunal segments injected with lactulose was more than 3 times that of the control ($p<0.01$). The segments treated with the extract had higher volumes of fluids compared to that of the control. The

difference, however, was not significant.

The transit time of the ingesta throughout the alimentary canal was measured according to the percentage of the marker dye, phenol red, in different parts of the digestive tract (Figures 5). Thirty minutes following intragastric administration of phenol red, the highest concentration of the marker was in the median section of the small intestine in both control and the test groups. There was no significant differences between the two experimental groups regarding the percentage of phenol red at this time (Figure 5-a). The ingesta seem to have propelled further for the second 30 min, with no statistically difference between the test and the control groups (Figure 5-b). The same story is true at 2 and 4 h following gavaging phenol red (Figures 5-c and 5-d respectively). Consistently, the geometric center of the dye in the treated animals was not significantly different from that of the control (Figure 6).

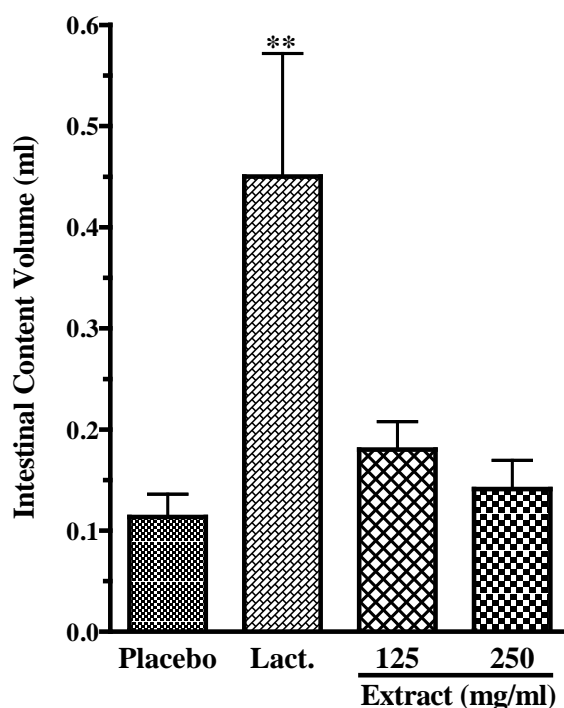


Figure 4. The volume of fluids in jejunal segments. Either the placebo, lactulose (Lact.) or ethanol extract of bitter almond (125 or 250 mg/ml) were injected into the jejunal segments of anesthetized rats ($n=9$) and 1 h later, the fluid volume in each segment was measured. Data are represented as mean+SEM. The asterisks indicate statistical significance ($p<0.01$, one-way ANOVA).

Figure 5-a

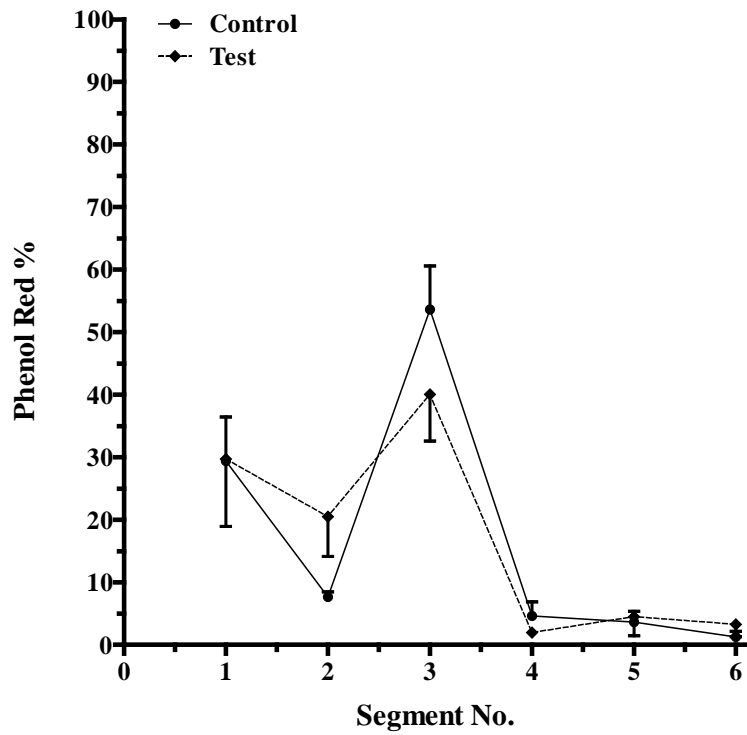


Figure 5-b

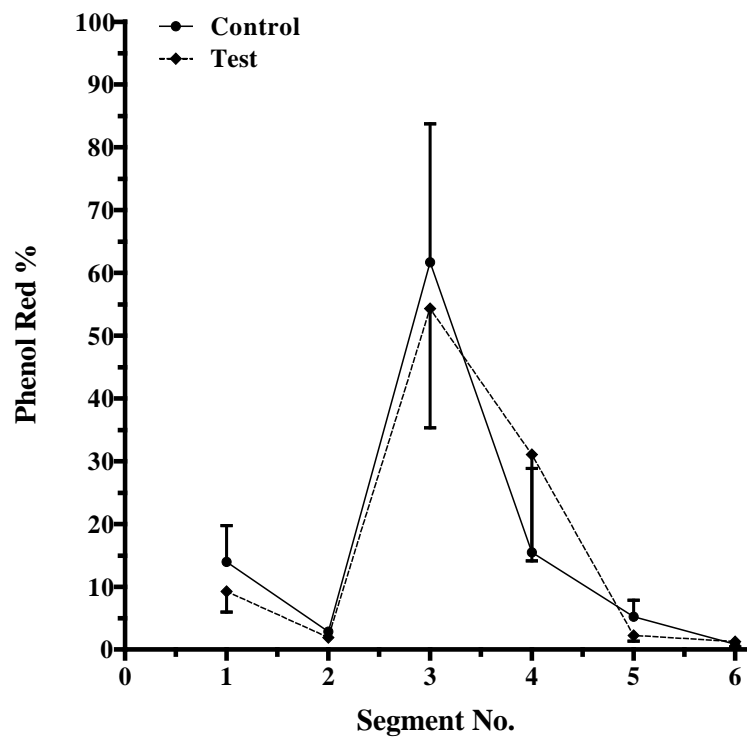


Figure 5-c

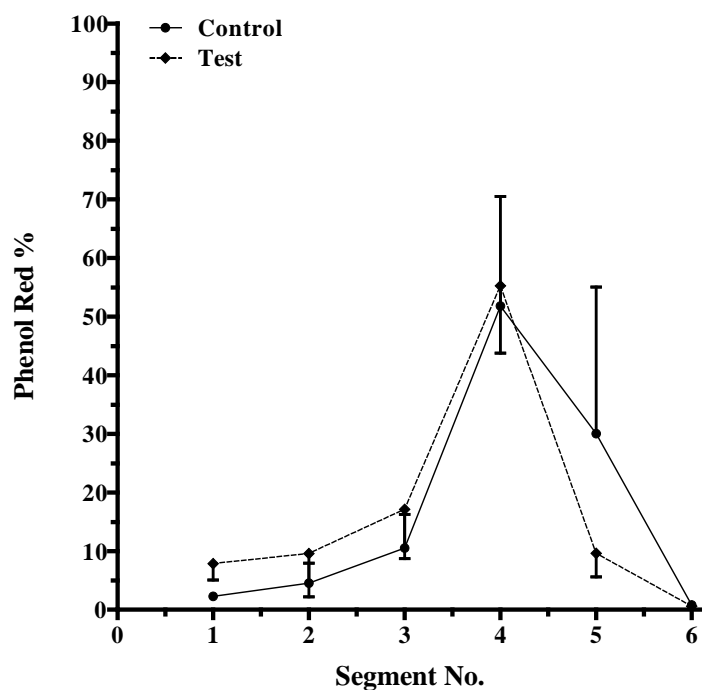


Figure 5-d

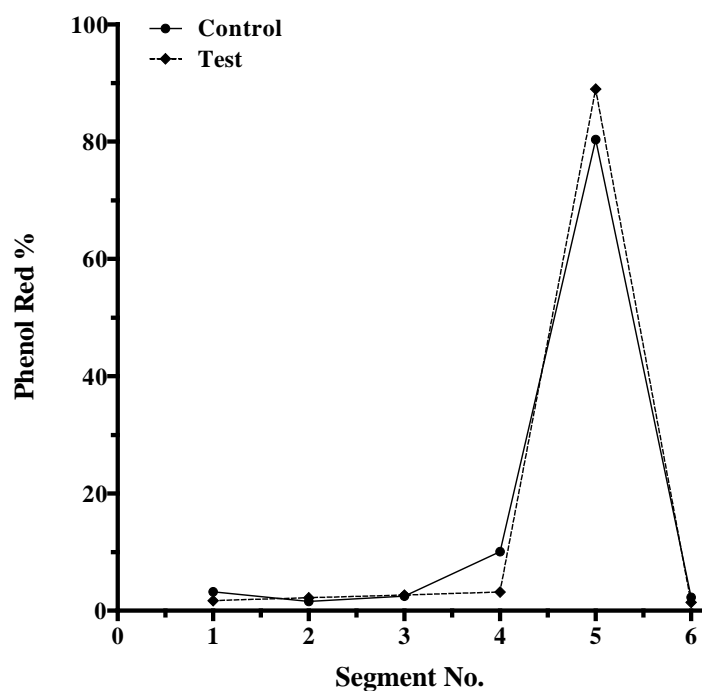


Figure 5. The percentage of phenol red in different GI segments of rats treated either with bitter almond extract or the placebo (n=3, each). The extract (250 mg/kg Bwt) or placebo were gavaged to fasted rats twice (18 h interval). Thirtymin following the last medication, all rats received phenol red and methyl cellulose and were euthanized after 30 min, 1, 2 and 4 h (figures a-d respectively). Gastrointestinal segments 1-6 represent stomach, proximal, middle and distal parts of small intestine, cecum and colon, respectively. Data are represented as mean \pm SEM (2-way ANOVA: n.s.).

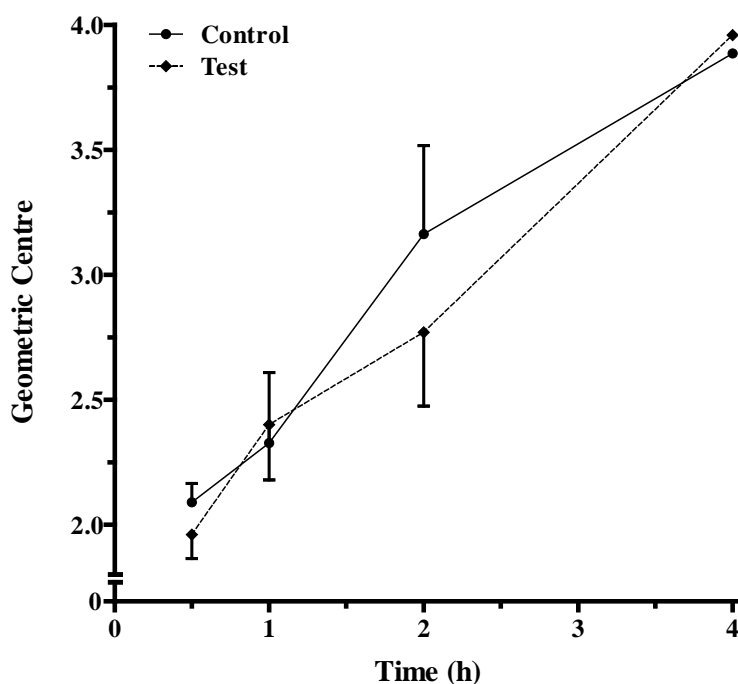


Figure 6. The geometric center of the marker, phenol red, within the intestine in fasted rats receiving ethanol extract of bitter almond (250 mg/kgBwt, twice with 18h interval) or the placebo. Data in each time-point represent replicates of 3 and are expressed as mean \pm SEM.

Discussion

The results in this research demonstrated a laxative effect in response to the ethanol extract of bitter almond. Since amygdalin seems to be the main component which differentiates bitter almond from sweet almond, it serves as the first candidate to mediate the observed GI effects. As one possibility, the laxative effect might have been caused by osmotic infiltration of fluids into the gut lumen (Gangarosa and Seibert, 2003). Amygdalin is decomposed into glucose and mandelonitrile, which is further hydrolyzed to benzaldehyde and hydrogen cyanide (Newmark *et al.*, 1981, Rietjens *et al.*, 2005). It has been suggested that GI microflora are involved in this reaction (Carter *et al.*, 1980, Shim and Kwon, 2010). Although hydrogen cyanide is rapidly absorbed by the GI tract (Martindale and Reynolds, 1989, Humphreys, 1998), the resultant glucose appears to be released into GI lumen beyond the absorptive epithelium, i.e. duodenal enterocytes.

Unabsorbed glucose and its metabolites can retain fluids within the lumen and account for the observed laxative effects. An alternative hypothesis for the observed laxative effect is drug induced intestinal secretion (Gangarosa and Seibert, 2003). Both possibilities were verified via intraluminal injection of the extract into jejunal segments. As expected, the fluid volume in segments injected with lactulose, a widely used osmotic laxative used as the positive control, was significantly higher than control group (placebo). However, the fluid volumes in jejunal segments injected with the extract were not statistically different compared to that of the control group.

Some laxative drugs are believed to decrease GI transit time by enhancement of GI propelling movements. Stimulant cathartics are a class of laxatives that exert their effect via irritation of the mucosa of GI tract and hence cause peristalsis (Brunton *et al.*, 2008). Benzaldehyde is believed to irritate the GI mucosa and cause diarrhea (Martindale and

Reynolds, 1989). On the other hand, probiotic effect may account for the observed laxative properties of bitter almond extract. This category of drugs accelerates transit of ingesta throughout the GI lumen by acting on certain receptors such as those of acetylcholine, dopamine, serotonin or motilin (Katzung *et al.*, 2009). The current study, however, did not show significant differences in transit time or the geometric center due to the treatment.

As mentioned earlier, hydrogen cyanide is one of the amygdalin metabolites. Small amount of this compound is well known to halt cellular oxidative processes (Hall and Rumack, 1986, Bromley *et al.*, 2005). Besides, the most majority of nutrients are absorbed from the GI tract via active, secondary active or tertiary active transport mechanisms, all of which depend on ATP. The laxative effect of bitter almond may be, therefore, a consequence of malabsorption (Cunningham and Klein, 2007). This hypothesis, however, should be further investigated in future studies.

In conclusion, the current research suggests a laxative effect for ethanol extract of bitter almond. Subsequent experiments on the mechanism of the laxative effect suggested it may not be osmotic, irritant, stimulant or prokinetic. It may be rather malabsorptive due to toxic effect of hydrogen cyanide on oxidative metabolism of enterocytes.

Acknowledgments

The authors are grateful to Ferdowsi University of Mashhad for financial support (Grant no: 15162/2).

References

- Abbaszadeh, M., Kazerani, H.R. and Kamrani, A. (2010). Laxative effects of *Rosa damascena* Mill in dogs. *Journal of Applied Animal Research* **38**, 89-92.
- Arezoomandan, R., Kazerani, H.R. and Behnam-Rasooli, M. (2011). The laxative and prokinetic effects of *Rosa damascena* Mill in rats. *Iranian Journal of Basic Medical Sciences* **14**, 161-169.
- Bromley, J., Hughes, B.G., Leong, D.C. and Buckley, N.A. (2005). Life-threatening interaction between complementary medicines: Cyanide toxicity following ingestion of amygdalin and vitamin C. *Annals of Pharmacotherapy* **39**, 1566-1569.
- Brunton, L., Parker, K., Blumenthal, D. and Buxton, L. (2008). Goodman and Gilman's Manual of Pharmacology and Therapeutics. McGraw-Hill Medical Publishing Division, New York.
- Carter, J. H., McLafferty, M.A. and Goldman, P. (1980). Role of the gastrointestinal microflora in amygdalin (laetrile)-induced cyanide toxicity. *Biochemical Pharmacology* **29**, 301-304.
- Cunningham, J.G. and Klein, B.G. (2007). Textbook of Veterinary Physiology. 4th edn., Saunders Elsevier, Missouri.
- Gangarosa, L.M. and Seibert, D.G. (2003). Drugs used in gastrointestinal disorders. In C.R. Craig, and Stitzel R. E., editors. Modern Pharmacology with Clinical Applications. 6th edn., Lippincott Williams & Wilkins, Hagerstown.
- Greenberg, D.M. (1980). The case against laetrile: the fraudulent cancer remedy. *Cancer* **45**, 799-807.
- Hall, A.H. and Rumack, B.H. (1986). Clinical Toxicology of Cyanide. *Annals of Emergency Medicine* **15**, 1067-1074.
- Heikkila, R.E. and Cabbat, F.S. (1980). The prevention of alloxan-induced diabetes by amygdalin. *Life Sciences* **27**, 659-662.
- Humphreys, D.J. (1998). Veterinary toxicology. 3rd edn., Baillier Tindall. London.
- Hwang, H.J., Kim, P., Kim, C.J., Lee, H.J., Shim, I., Yin, C.S., Yang, Y. and Hahm, D.H. (2008). Antinociceptive effect of amygdalin isolated from *Prunus armeniaca* on formalin-induced pain in rats. *Biological and Pharmaceutical Bulletin* **31**, 1559-1564.

- Jiagang, D., Li, C., Wang, H., Hao, E., Du, Z., Bao, C., Lv, J. and Wang, Y. (2011). Amygdalin mediates relieved atherosclerosis in apolipoprotein E deficient mice through the induction of regulatory T cells. *Biochemical and Biophysical Research Communications* **411**,523-529.
- Katzung, B.G., Trevor, A.J. and Masters, S.B. (2009). Basic and Clinical Pharmacology. 11th edn., McGraw-Hill Medical. New York.
- Lin, W.C. and Lin, J.Y. (2011). Five bitter compounds display different anti-inflammatory effects through modulating cytokine secretion using mouse primary splenocytes *in vitro*. *Journal of Agricultural and Food Chemistry* **59**,184-192.
- Martindale, W. and Reynolds, J.E.F. (1989). Martindale the Extra Pharmacopoeia. The Pharmaceutical Press. London.
- Martinez, V., Wu, S.V. and Taché, Y. (1998). Intracisternal antisense oligodeoxynucleotides to the thyrotropin-releasing hormone receptor blocked vagal-dependent stimulation of gastric emptying induced by acute cold in rats. *Endocrinology* **139**,3730-3735.
- Milazzo, S., Lejeune, S. and Ernst, E. (2007). Laetrile for cancer: a systematic review of the clinical evidence. *Supportive Care in Cancer* **15**,583-595.
- Mir-Heidar, H. (1995). Ma'arefGiahi. Vol 1, 2nded., DaftarNashrFarhangIslami. Tehran (Persian).
- Newmark, J., Brady, R.O., Grimley, P.M., Gal, A.E., Waller, S.G., Thistlethwaite, J.R. (1981). Amygdalin (Laetrile) and prunasin beta-glucosidases: distribution in germ-free rat and in human tumor tissue. *Proceedings of the National Academy of Sciences of the United States of America* **78**, 6513–6516.
- Rietjens, I.M., Martena, M.J., Boersma, M.G., Spiegelberg, W. and Alink, G.M. (2005). Molecular mechanisms of toxicity of important foodborne phytotoxins. *Molecular Nutrition and Food Research* **49**,131-158.
- Sánchez-Pérez, R., Jørgensen, K., Olsen, C.E., Dicenta, F. and Møller, B.L. (2008). Bitterness in almonds. *Plant Physiology* **146**,1040-1052.
- Shim, S.M. and Kwon, H. (2010). Metabolites of amygdalin under simulated human digestive fluids. *International Journal of Food Sciences and Nutrition* **61**,770-779.
- Vickers, A. (2004). Alternative cancer cures: "unproven" or "disproven"? *CA: A Cancer Journal for Clinicians* **54**,110-118.
- Zargari, A. (1992). Medicinal Plants, Vol 2. 5th edn., Tehran University Press. Tehran.

بررسی اثرات ملین بادام تلخ (*Amygdalus communis* var. *amara*)

حمید رضا کازرانی^۱، صدیقه جلالی^۲

گروه فیزیولوژی، دانشکده دامپزشکی، دانشگاه فردوسی مشهد، مشهد، ایران
گروه زیست شناسی، دانشگاه پیام نور، تهران، ایران

دریافت مقاله: ۱۳۹۱/۱۱/۲۰ پذیرش نهایی: ۱۳۹۲/۱۲/۱۹

چکیده

در این پژوهش اثرات پروکینتیک و ملین احتمالی بادام تلخ مورد مطالعه قرار گرفت: ۱- دو گروه ۷ تایی موش صحرایی توسط گاوژ به ترتیب عصاره اتانولی بادام تلخ (500 mg/kg) و یا دارونما دریافت نمودند و تعداد، وزن و درصد آب مدفوع آنها ۱۸-۲۴ ساعت پس از درمان مورد بررسی قرار گرفت. ۲- عصاره اتانولی بادام تلخ (۱۲۵ و ۲۵۰ mg/ml)، لاکتولوز (به عنوان کنترل مثبت) و یا دارونما به صورت تصادفی به قطعات ژنوم موش‌های صحرایی که تحت بیهوشی قرار داشتند تزریق گردید (n = ۹). حجم هر قطعه پس از یک ساعت اندازه گیری شد. ۳- زمان عبور از دستگاه گوارش موش‌های صحرایی که توسط عصاره بادام تلخ و یا دارونما درمان شده بودند با استفاده از فنول قرمز بررسی شد. موش‌ها پس از ۳۰ دقیقه، ۱، ۲ و ۴ ساعت قربانی شدند. عصاره اتانولی بادام تلخ به میزان 500 mg/kg به طور معنی داری موجب افزایش وزن و آب مدفوع موش‌های مورد مطالعه گردید. این عصاره هیچ تأثیری روی نشت اسمزی مایعات به داخل روده و یا زمان عبور محتویات از لوله گوارشی نداشت. نتایج این پژوهش حاکی از اثرات ملین برای بادام تلخ می باشد. به نظر می رسد این تأثیر از اختلال در جذب الکترولیت‌ها و آب توسط انتروسیت‌ها ناشی گردد.

واژگان کلیدی: بادام تلخ، ملین، پروکینتیک